

CORNEA

Managing Blepharitis: Tried-and-True and New Approaches

BY ANNIE STUART, CONTRIBUTING WRITER

INTERVIEWING J. DANIEL NELSON, MD, HENRY D. PERRY, MD, AND SCHEFFER C. G. TSENG, MD, PHD

Thanks to the efforts of the International Workshop on Meibomian Gland Dysfunction, clinicians now have a road map for classifying and managing this condition.¹ The workshop standardized the definition of meibomian gland dysfunction (MGD), which can be one component of eyelid inflammation, called blepharitis.

Blepharitis, which often contributes to dry eye syndrome, can cause many ocular symptoms, including itching, grittiness, photophobia, eyelid crusting, and red, swollen eyes. Beyond causing patient discomfort, the presence of blepharitis can affect the outcomes of cataract and refractive surgery. And, as the prevalence of blepharitis increases with age, clinicians can expect to see a growing number of cases in the coming years.

How can ophthalmologists best manage this common, yet complex, condition? Starting with how to assess symptoms to determine appropriate treatment, three experts outline their approaches—with an eye to the tried-and-true, as well as to newer techniques—that maybe prove helpful for some patients.

The Significance of Symptoms

A thorough ophthalmologic evaluation, along with a careful history, is critical for zeroing in on the best treatment approaches. Henry D. Perry, MD, chief of the cornea service at Nassau University Medical Center in East Meadow, N.Y., asks patients to

complete the Ocular Surface Disease Index questionnaire to determine their symptoms, environment, and overall functioning. “This gives me an ability to quickly assess the significance of the problem on a scale of mild, moderate, or severe,” he said.

Tests. In addition, Dr. Perry performs a number of tests to pinpoint whether symptoms are related to dry eye or MGD plus dry eye; these may include Schirmer tests without anesthesia, tear osmolarity tests, and lissamine green and fluorescein staining. “We also do meibomian gland expression, which helps us further categorize the degree of the problem,” said Dr. Perry.

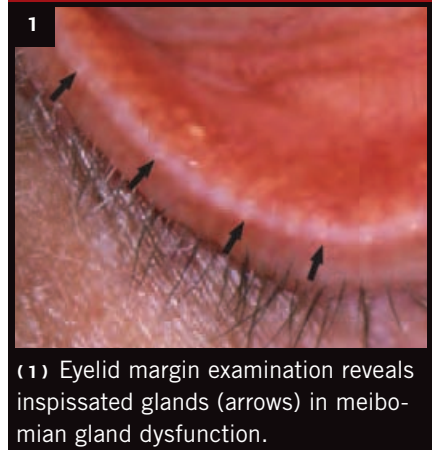
Dear diary. J. Daniel Nelson, MD, professor of ophthalmology at the University of Minnesota, in Minneapolis, involves patients in tracking clues to their condition. When symptoms arise, he has patients ask themselves three basic questions:

1. **Is it me?** Do I have a systemic condition, such as rosacea or lupus that’s become active? Are my joints achy? How am I feeling overall? Where am I in my menstrual cycle? The last question can be important, Dr. Nelson noted, because estrogen promotes inflammation.

2. **Is it something I did?** Did I switch cosmetics or just get my nails or hair done? Did I start a new medication?

3. **Is it my environment?** Have I started a new job or moved into a new place? Have I taken up a new hobby, such as painting?

Evidence of MGD



(1) Eyelid margin examination reveals inspissated glands (arrows) in meibomian gland dysfunction.

If patients can predict when symptoms will worsen, they can also be more aggressive with treatment, as needed, said Dr. Nelson. And even though blepharitis is typically treated only when symptoms are present, asymptomatic blepharitis may also need to be addressed before ocular surgery, he added.

First Step: Patient Self-Care

Patient self-care plays a major role in the management of blepharitis.

Fatty acids. Omega-3 fatty acids are known to be anti-inflammatory, said Dr. Nelson. He starts some blepharitis patients on supplements of 1 to 3 g, two to three times daily. He advises, however, that it can take six to 12 months to see a definite effect. A small randomized clinical trial shows that omega-3 supplements are beneficial for MDG and blepharitis,² but more

and larger studies are needed to clarify the role of supplementation and other factors.

Can't beat heat. "In my mind, the key treatment for these patients is heat," said Dr. Nelson. "I have patients apply five minutes of moist heat at bedtime and first thing in the morning." Dr. Perry prefers heat in the form of warm saltwater soaks, which he says are more isotonic and thus more comfortable and less likely to wrinkle the eyelid skin. His regimen is four times a day for two weeks, then twice a day for a month, and twice a week after that.

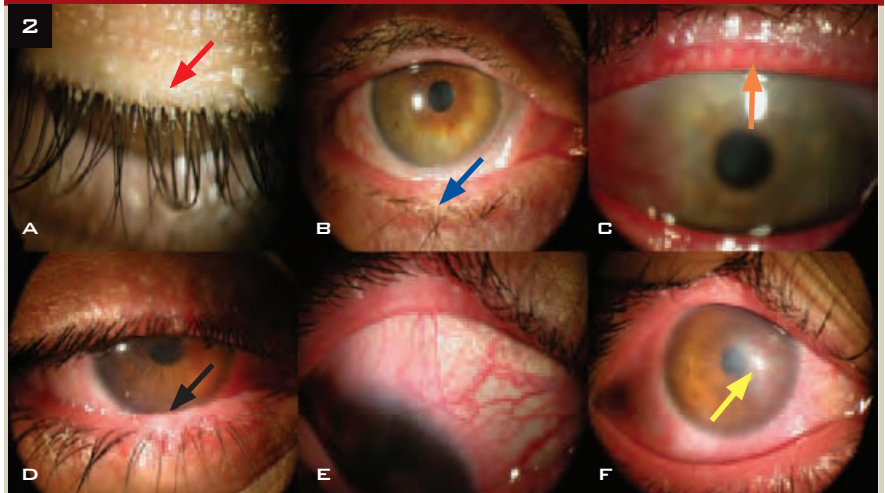
He explains to patients how the meibomian glands can become clogged, leading to a change in meibum composition from long-chain fatty acids to free fatty acids. "FFAs, combined with inflammation, cause saponification," said Dr. Perry, who photographs the patient's foamy tear film to demonstrate. He tells patients how heating the eyelid margin transforms fats—solid at room temperature—to a liquid, which gets secretions flowing again.

Eyelid scrubs. Hygiene products come and go, said Dr. Perry. "And about 10 percent of people have an allergic component such as eczema or atopic dermatitis," he said. "When you put a chemical on these patients, they won't do well. That's why I stick to saltwater soaks."

Dr. Nelson added that while lid scrubs can occasionally be irritating, part of the problem lies in technique. "Patients often pull down the lid and scrub the conjunctiva, rather than the lid margin," said Dr. Nelson, "so they actually irritate their lids." Thus, dexterity can be an issue, and instruction is critical.

Eyelid compression. Dr. Nelson has largely dispensed with lid scrubs and focuses instead on gentle compression, not rubbing, of closed eyelids—with or without the use of an eye pad. If blepharitis is severe, however, he instructs patients on how to use a cotton-tipped applicator to remove the cap of oil from the gland orifice. He also advises the daytime use of artificial lubricants to help wash out the eyes.

Mighty Mites?



Although the connection between *Demodex* mite infestation and blepharitis has been reported since at least the early 1960s,¹ it may be overlooked by clinicians. Recent research points to a strong correlation between levels of *Demodex* and the severity of blepharitis (Fig. 2).² "When we eradicate or cut down infestations, we can see patients improve," said Scheffer C. G. Tseng, MD, PhD, medical director of the Ocular Surface Center in Miami.

Subset susceptibility. More than 8 in 10 people over age 60 are infested with *Demodex*.² But some are troubled by the presence of *Demodex* mites, while others have no symptoms, said Dr. Tseng. He drew an analogy to the house-dust mite—some people can live with it and never get sick, but others have asthma attacks.

In addition to precipitating hypersensitivity reactions, mites may cause direct damage, such as eyelash disorders, and may block meibomian glands. "They may also be a vector for a species of bacillus that causes rosacea-like problems," said Dr. Tseng.

Demodex diagnosis. "*Demodex* infestation is much more commonly found in patients who don't respond to other treatment," said Dr. Perry. With recalcitrant cases, Dr. Perry first uses a slit lamp to check for cylindrical dandruff (Fig. 2A), a very common sign of mites. If he finds it, he removes an eyelash and checks for mites under a microscope.

When mites mate. On average, mites have a three-week lifespan, and hygiene is critical for interrupting their life cycle, said Dr. Tseng. "Mites should die out if you don't let them mate." Unfortunately, eyelids are less accessible to thorough cleaning because they are surrounded by the nose, eyebrow, and cheekbone.

Tea tree oil. With both antimicrobial and anti-inflammatory effects, tea tree oil has been effective at eradicating mites, said Dr. Tseng, in either 50 percent lid scrubs or 5 percent lid massages. Because higher concentrations can be irritating, however, his team (with research supported by the National Eye Institute) worked to identify the active ingredient in tea tree oil for killing mites. They have developed a treatment containing this ingredient, which is better tolerated by patients. Dr. Tseng said, "This new lid scrub regimen, known as Cliradex, will be available this year."

1 Post CF et al. *Arch Dermatol.* 1963;88:298-302.

2 Liu J et al. *Curr Opin Allergy Clin Immunol.* 2010;10(5):505-510.

Novel Therapies

Blinking. Expression of the meibomian glands is also important. Meibomian glands secrete oil by nerve action and the mechanical action of blinking, said Dr. Nelson. But the rate of blinking decreases with age and near vision tasks such as computer use. “I’ve been amazed how symptoms will resolve just with heat and blinking exercises,” he said, noting that this is the main change he’s instituted in recent years. He advises patients to concentrate on blinking at least 20 times, four times a day.

Add Medications If Needed

If self-care measures are not effective, medication may be needed.

Topical antibiotics. Dr. Nelson adds an antibiotic, such as erythromycin or bacitracin ointment, if inflammation remains a problem. “I start with erythromycin ointment at bedtime because it has both antibiotic and anti-inflammatory effects and is really cheap.” Instead of squirting the medication into the eye, Dr. Nelson has patients put a little on a fingertip and wipe it across the closed eyelid near the lashes. Medication applied in this way reaches the meibomian glands and conjunctiva quite effectively, he said.

For acute anterior blepharitis, Dr. Perry prefers bacitracin ointment, a potent option with good results over short periods of time. He noted that erythromycin has a place for infectious blepharitis in patients who are sensitive to bacitracin, but resistance rates as high as 50 percent remain a big concern.³

A new option. For chronic cases of blepharitis, Dr. Perry routinely uses AzaSite after lid massage. This new option consists of azithromycin in a viscous, mucoadhesive ophthalmic formulation that is effective against gram-positive and gram-negative bacteria.⁴ “It has good penetration and lasts a long time—usually for a week or two.”

Oral antibiotics. For posterior blepharitis, long-term oral tetracycline, minocycline, or doxycycline is more effective than topical antibiotics, said Dr. Perry, especially for patients

A few newer treatments have made it to market, said Dr. Nelson, but have not undergone sufficient randomized clinical trials to prove their benefit and cost-effectiveness.

Intense pulsed light. Developed by Rolando Toyos, MD, intense pulsed light (IPL) therapy was first used by dermatologists for treating rosacea, said Dr. Nelson. Operating much like a heat lamp, the treatment is now also used for patients with MGD.

Thermal pulsation. “LipiFlow is an interesting device that provides heat and expresses the lacrimal gland, similar to the combined action of blinking and warm compresses,” said Dr. Nelson. Approved by the FDA, the 12-minute LipiFlow Thermal Pulsation Treatment (TearScience) is not yet covered by insurance, and it generally costs approximately \$1,500 to \$2,000 for both eyes. It appears to provide months of relief, said Dr. Perry. “But I’m troubled by the expense.”

Duct probing. Meibomian gland duct probing, using probes invented by Steven Maskin, MD, works by physically opening up the occlusion caused by MGD. “Due to discomfort, it requires anesthetizing the patient’s lids before passing a small blunt cannula probe into the meibomian glands,” said Dr. Nelson.

with rosacea. “As little as one pill twice a week can maintain a relatively good therapeutic dose in these patients for long periods.”

Cyclosporine. Dr. Nelson finds topical cyclosporine to be more effective for blepharitis than for severe dry eye, although the results are not instantaneous.⁵ “If I’m considering it, I’ll start out with a topical steroid and then switch to cyclosporine.” One disadvantage, he said, is that it can lead to eye irritation.

Steroids. Although steroids such as loteprednol ointment and antibiotic-steroid combinations such as tobramycin-dexamethasone (TobraDex) or prednisolone-sulfacetamide (Blephamide) can work well, they’re not ideal, said Dr. Nelson. “As you increase the intensity of therapy, you increase the risk of side effects or complications,” he said. “With steroids, you always have to worry about infection, cataract development, and increased IOP.”

Dr. Perry added another cautionary note: “Not all cases of blepharitis are due to MGD or allergy or staph infections. Some are actually caused by herpetic infections. I’ve seen two or three cases that worsened from corticosteroid use.”

1 Report of the TFOS Workshop on Meibomian Gland Dysfunction. *Invest Ophthalmol Vis Sci*. Special Issue. 2011;52(4):1917-2085. Available at: www.iovs.org/content/52/4.toc.

Note: This report was discussed extensively in *EyeNet*, July/August 2011, Clinical Update: Cornea, pp 27-29.

2 Macsai MS. *Trans Am Ophthalmol Soc*. 2008;106:336-356.

3 Back EE et al. *Antimicrob Agents Chemother*. 2012;56(2):739-742.

4 Utine CA. *Clin Ophthalmol*. 2011;5:801-809.

5 Perry HD et al. *Cornea*. 2006;25(2):171-175.

Dr. Nelson is a consultant with Santen Pharmaceuticals. Dr. Perry is a consultant for Allergan. Dr. Tseng has a financial interest in tea tree oil used for treating Demodex blepharitis.

More at the Meeting

For further information about MGD and blepharitis, visit the **Cornea Subspecialty Day, Section I: Management of Ocular Surface Diseases—**


Show Me the Evidence (Saturday, Nov. 10, 8:05 to 9:30 a.m.).

And, at the Joint Meeting, you can learn more about the new approaches mentioned in this article at instruction course 492: **Next-Generation Technologies for the Diagnosis and Treatment of Dry Eye and Meibomian Gland Dysfunction** (Tuesday, Nov. 13, 9 to 10 a.m.).



2012-2013 Basic and Clinical Science Course

Your trusted resource for ophthalmic clinical knowledge and scientific research



Long recognized as the gold standard of ophthalmic references, the Academy's BCSC is an essential resource for practicing ophthalmologists and residents worldwide. Each of the 13 sections includes up-to-date clinical knowledge, concise information and tables, and references for further study. The BCSC is continually revised by a faculty of more than 80 leading ophthalmologists. **CME**

This year's major revisions:

Section 10: Glaucoma

Section 11: Lens and Cataract

Section 12: Retina and Vitreous


13 sections
3,000+ full-color images
Print and eBook formats
Up to 55 self-assessment questions per section, with answers and discussions

Earn AMA PRA Category 1 Credits™

BCSC eBooks – Available this Summer!

The all-new eBook format is completely different than any previous electronic BCSC product. eBooks are not Flash apps or Apple iBooks, which means they can be used on nearly any computer, tablet or smartphone with an Internet connection. Purchase them as individual sections or save with a complete set!

eBooks available to order Summer 2012.



The American Academy of Ophthalmology is accredited by the Accreditation Council for Continuing Medical Education to provide continuing medical education for physicians.

For more information or to order, visit www.aao.org/BCSC or call +1 415.561.8540.

 **AMERICAN ACADEMY OF OPHTHALMOLOGY**
The Eye M.D. Association